

## LOCAL RADIOTHERAPY FOR PEDAL MANIFESTATIONS OF HLA-B27-RELATED ARTHROPATHY

BY V. GRILL\*, M. SMITH†, M. AHERN‡ AND G. LITTLEJOHN§

§Monash Medical Centre, †Flinders Medical Centre, ‡Flinders University of S. Australia and \*Prince Henry's Hospital, Melbourne, Australia

### SUMMARY

Four males with characteristic foot manifestations of HLA-B27-related arthropathy are reported. The severity of this problem and its recalcitrance to standard therapies led to the use of local radiotherapy. The beneficial outcome and minimal short-term side effects of this treatment are discussed in relation to previous experience with radiotherapy in ankylosing spondylitis.

KEY WORDS: HLA-B27, Radiotherapy, Spondyloarthropathy, Enthesopathy.

THE spondyloarthropathies are linked by characteristic clinical features and the usual presence of the HLA-B27 antigen. The predominant musculoskeletal features relate to inflammation of the enthesis where tendons or ligaments insert into bone. Once inflammation is triggered in these regions it may be quite intense and lead to significant morbidity. In the periphery, the foot is a common target area. Standard anti-inflammatory treatments may not control such inflammation. We describe four patients in whom intense inflammation of enthesal areas and joints in the feet was resistant to standard treatment but whose symptoms resolved completely with radiotherapy treatment. These were the only patients with this problem treated with radiotherapy in our units during the last 7 years. We discuss the implications of this observation.

### CASE REPORTS

#### Case 1

A 24-year-old carpenter presented in 1984 with a 6-year history of bilateral heel and foot pain, swelling of the left first metatarsophalangeal joint and bilateral Achilles tendonitis. Over this period he had received physiotherapy, various non-steroidal anti-inflammatory drugs (NSAIDs), corticosteroid injections and cushion supports. Despite this his inflammation persisted. Examination showed a right Achilles tendonitis and a swollen and tender left first metatarsophalangeal joint. There was tenderness over the plantar fascial

insertions into both calcanei. There was no evidence of sacroiliitis nor other extraspinal features of the spondyloarthropathy group of diseases.

Full blood examination and erythrocyte sedimentation rate (ESR) were normal. Rheumatoid factor was absent but the HLA-B27 antigen was present. Radiographs showed new bone formation at both plantar fascial insertions into the calcaneum with erosion and fluffy new bone at the right Achilles insertion (Fig. 1). Erosions of the left first metatarsophalangeal joint were also noted. Temporary and variable response to high dose indomethacin and phenylbutazone together with local corticosteroid injections to the affected regions occurred over the next 6 months.

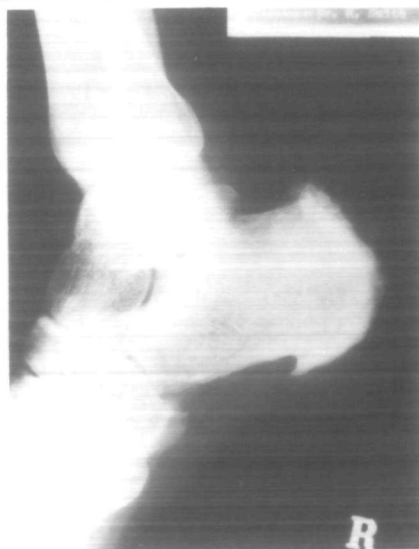


Fig. 1—Case 1, inferior heel spur and fluffy periosteal reaction at the Achilles insertion.

Submitted 18 August 1987; revised version accepted 10 February 1988.

Address for correspondence: Dr. G. Littlejohn, Prince Henry's Hospital, St. Kilda Road, Melbourne, 3004, Australia.

However, because of persisting recalcitrant inflammation with pain and inability to pursue his career, a course of radiotherapy was given in July 1985. The patient received a total of 1000 rads to both heels given in 10 treatments over 2 weeks without side effects. Within 1 month of completion of the radiotherapy the symptoms had resolved and 25 months later, the patient remained free of symptoms without the need for medication and was working full time.

#### Case 2

A 21-year-old male university student developed gradual onset of right heel pain in December 1983. Two months later a painful swollen first metatarsophalangeal joint developed and later still right plantar fasciitis, right Achilles tendonitis and left knee synovitis occurred. Physiotherapy, cushion supports, anti-inflammatory medication and local injections gave only temporary relief. Examination showed a right Achilles tendonitis and a swollen tender right first metatarsophalangeal joint. There was no evidence of sacroiliitis. Full blood examination and ESR were normal. The patient was HLA-B27 positive. Radiographs showed erosive changes at the insertions of the Achilles tendon and plantar fascia into the calcaneum and of a first metatarsophalangeal joint. Despite the treatments outlined in the previous case given over a 9-month period, the patient's symptoms persisted and interfered with his studies. In October 1985 he had local radiotherapy to both feet, receiving 1000 rads during 10 treatments over 2 weeks. He reported complete recovery during the following weeks and 22 months later he remained free of symptoms.

#### Case 3

A 36-year-old salesman was initially seen in February 1984 with a 3-week history of left ankle synovitis and right second metatarsophalangeal joint inflammation. The synovitis of the left ankle and the right second metatarsophalangeal joint resolved with local injection and indomethacin. Over the ensuing 2 years he had several similar episodes. In 1986 he developed intense pain in the left mid-foot and the right metatarsophalangeal joint. These did not respond despite high dose phenylbutazone, systemic and local corticosteroids. Investigations showed that full blood examination and ESR were normal. The patient was HLA-B27 positive. Radiographs of

the foot were normal but a bone scan showed increased uptake in the region of the medial cuneiform bones, ankles and other sites in the feet. Persistent symptoms and an inability to walk freely prompted treatment with 2500 rads to both feet given in 10 equal treatments over a 2-week period. Improvement started within 2 weeks of initiating therapy. Thirteen months later, his feet were symptom free. During treatment he experienced temporary loss of nails and hair. He has subsequently had further episodes of synovitis of the left knee.

#### Case 4

An 18-year-old student presented in June 1985 with a 5-month history of inflammation of the right Achilles tendon insertion and the left first metatarsophalangeal joint. Over a 4-month period the patient's symptoms settled only temporarily after repeated local corticosteroid injections, high dose phenylbutazone, indomethacin and oral corticosteroid treatment. The patient could not walk on his painful foot at the end of each day. There was a 10-year history of recurrent acute anterior uveitis which was treated with topical corticosteroid and atropine. There was also an 8-year history of recurring inflammation of the ankles which had previously responded to local injection and NSAIDs. He received 10 doses of 150 rads of radiotherapy over 2 weeks and 1 month later he reported that all symptoms in the feet had disappeared. Review 21 months after treatment showed that there had been no further episodes of foot discomfort. He remained asymptomatic and was working full time.

### DISCUSSION

The pathogenesis of HLA-B27 related inflammation is unknown but the resultant inflammation seems to differ from that of rheumatoid arthritis. It is more responsive to indomethacin or phenylbutazone and is known to be radiosensitive. The beneficial effect of high voltage radiotherapy for spondyloarthropathy was demonstrated in the 1950s [1-5]. In addition to axial radiotherapy such patients were also given peripheral radiotherapy and good results were noted [1]. In Sharp's study [2] no significant difference was observed between the behaviour of peripheral sites treated alone, and those treated concurrently with the spine, suggesting that the effect of deep radiotherapy was local. However, this treatment option was largely discontinued when it was appreciated

that there was a risk of leukaemia and solid tumours [6-10]. These late complications were dose related following irradiation of spinal areas with large mean bone marrow radiation doses.

Mantell [11] reported 17 patients who received radiotherapy for painful heel conditions, 11 of whom responded. Six of the 17 patients had clinical features in keeping with spondyloarthropathy and five of these six improved.

We have reported four young males, all of whom were HLA-B27 positive and all of whom had incapacitating symptoms of their feet. They had all received adequate trials of NSAIDs in optimal doses. The majority of patients do respond to such measures and it is only in the recalcitrant patient that more aggressive treatment should be considered. Sulphasalazine, methotrexate and azathioprine were not used in view of the local nature of the problems. We have shown that radiotherapy in low dose to local areas leads to prompt and prolonged resolution of symptoms.

The short-term side effects were few but the foot cannot tolerate high doses of radiotherapy which may lead to local necrosis. Theoretical side effects include radiation-induced bone tumour or necrosis but this is considered a most unlikely risk at the doses used here [11]. The long-term effects are unknown.

## REFERENCES

1. Desmarais MHL. Radiotherapy in arthritis. *Ann Rheum Dis* 1953;12:25-8.
2. Sharp J, Easson EC. Deep X-ray therapy in spondylitis. *Br Med J* 1954;1:619-23.
3. Wilkinson M, Bywaters EGL. Clinical features and course of ankylosing spondylitis. *Ann Rheum Dis* 1958;17:209-28.
4. Hart FD. Ankylosing spondylitis. *Br Med J* 1958;2:1082-3.
5. Howard N. The value of irradiation in ankylosing spondylitis. *Br J Radiol* 1957;30:371-4.
6. Court Brown WM, Abbatt JD. The incidence of leukaemia in ankylosing spondylitis treated with X-rays. A preliminary report. *Lancet* 1955;i:1283-5.
7. Stewart JW, Dische S. Effect of radiotherapy on bone-marrow in ankylosing spondylitis. *Lancet* 1956;ii:1063-7.
8. Abbatt JD, Lea AJ. The incidence of leukaemia in ankylosing spondylitis treated with X-rays. *Lancet* 1956;ii:1317-20.
9. Court Brown WM, Doll R. Mortality from cancer and other causes after radiotherapy for ankylosing spondylitis. *Br Med J* 1965;2:1327-32.
10. Smith PG, Doll R. Mortality among patients with ankylosing spondylitis after a single treatment course with X-rays. *Br Med J* 1982;284:449-60.
11. Mantell BS. Radiotherapy for painful heel syndrome. *Br Med J* 1978;2:90-1.